

Microscopic Analysis and Significance of Vascular Architectural Complexity in Renal Cell Carcinoma

Edmond Sabo, Albina Boltenko, Yanina Sova,
Avi Stein, Shira Kleinhaus, and
Murray B. Resnick¹

Departments of Pathology [E. S., A. B., Y. S., S. K., M. B. R.] and Urology [A. S.], Carmel Medical Center and Technion-Bruce Rappaport Faculty of Medicine, Haifa 34362, Israel

ABSTRACT

The objective of this study was to evaluate the utility of measuring microvessel fractal dimension (MFD) as a parameter of architectural microvascular complexity in localized renal cell carcinoma (RCC). Forty-nine patients with low-stage clear cell RCC were assessed in a 9-year follow-up retrospective study. Tumor vessels were visualized with the endothelial marker CD34. Tumor microvessel density (MVD) was measured by computerized morphometry. Fractal analysis of the RCC microvascular network was performed and the MFD was computed in each case. Correlation between tumor vascular parameters, histological grade, extent of tumor necrosis and patient survival were tested by uni- and multivariate analyses. A significant correlation was found between tumor grade and decreased survival ($P = 0.04$). The extent of macroscopic tumor necrosis also significantly correlated with poor prognosis ($P = 0.0001$). Survival analysis revealed a significantly higher MVD in patients who survived longer than 5 years as compared with those who died before the end of the 5-year follow-up period (MVD = $10.8 \pm 4.7\%$ versus $6.4 \pm 3.7\%$; $P = 0.03$). MVD was also inversely associated with the extent of tumor necrosis ($P = 0.03$). Microvessel fractal dimension was significantly higher in low- as compared with high-grade tumors (1.55 ± 0.11 versus 1.45 ± 0.15 ; $P = 0.03$). Survival analysis revealed a significantly higher MFD in those who lived >5 years as compared with those who died earlier (1.56 ± 0.11 versus 1.46 ± 0.15 ; $P = 0.02$). The MFD was inversely associated with the extent of tumor necrosis ($P = 0.01$). Multivariate analysis revealed that the MFD was the only significant factor to correlate with tumor necrosis, and that tumor necrosis was the only independent predictor of patient survival. These results indicate that the analysis of MFD as a marker of tumor microvascular complexity may

provide important prognostic information as well as novel insight into the biology of tumor angiogenesis.

INTRODUCTION

The measurement of intratumoral MVD² has proven to be an important prognostic indicator for many malignant neoplasms (1). The value of MVD as a predictor of patient prognosis in RCC is controversial (2–6) because certain reports revealed a direct correlation between MVD and survival (2, 3), others revealed an inverse correlation (4, 5), and one report showed no correlation (6). Kohler *et al.* (7) reported an inverse correlation between MVD and RCC grade. Measurement of tumor MVD does not take into account the microvessel architectural complexity, defined by the degree of vascular branching, irregularity, and tortuosity (8).

Fractal analysis is used in biology and medicine as a method for quantifying structural complexity (9, 10). Thus, irregularly tortuous contours and branching structures such as those seen in the tumor microvasculature, are best characterized by their fractal dimension. Recently, Baish and Jain (11) have reviewed the utility of fractal analysis in determining vascular complexity in malignant tumors. Planar imaging studies conducted by these authors on murine tumors, have shown that the vasculature of malignant tumors exhibits higher fractal dimensions computed by the box-counting method, as compared with blood vessels of the normal organs of origin (12). Fractal analysis of blood vessels in androgen-dependent mouse tumors revealed a decrease in the vascular architectural complexity with the removal of the androgen source (13). Different fractal measuring methods based on power law behavior of the Fourier spectrum of gray-scale images were applied by Heymans *et al.* (14) to characterize the microvasculature in cutaneous melanomas. These authors showed that fractal analysis helps to objectively quantify differences in the tumoral microvessel profile of malignant melanoma (14).

The prognostic role of microvessel architectural complexity as assessed by microscopy has not yet been established for any malignant neoplasm. This study is the first to determine whether the degree of vascular complexity has predictive value in the prognosis of RCC patients. The second aim of this study is to objectively determine by computer morphometry whether MVD has prognostic significance in RCC. The complex relationships between tumor vascular parameters, tumor grade, and prognosis are also discussed.

MATERIALS AND METHODS

Patients and Tumors. Our study group included tissue sections from 49 patients with low-stage clear cell RCC, (*i.e.*,

Received 10/13/00; accepted 1/5/01.

The costs of publication of this article were defrayed in part by the payment of page charges. This article must therefore be hereby marked *advertisement* in accordance with 18 U.S.C. Section 1734 solely to indicate this fact.

¹ To whom requests for reprints should be addressed, at Department of Pathology, Carmel Medical Center, 7 Michal Street, Haifa 34362, Israel. Phone: 972-4-825-0845; Fax: 972-4-825-0816; E-mail: resnick_murray@clalit.org.il.

² The abbreviations used are: MVD, microvessel density; RCC, renal cell carcinoma; MFD, microvessel fractal dimension.

stages 1 and 2) according to the criteria outlined by the American Joint Committee Tumor-Node-Metastasis classification (15) who were admitted consecutively to the Carmel Medical Center between the years 1990–1993. Follow-up information for 5 years or more was available for all patients. Paraffin blocks from RCC tumors were sectioned at 4 μm thickness and stained by H&E. Tumors were graded using the classification of Fuhrman *et al.* (16). Tumors were considered necrotic if they exhibited >25% macroscopic necrosis.

Immunohistochemical Staining. Tissue sections were immunohistochemically stained using monoclonal antibodies for the endothelial marker CD34 (QEnd/10,1:20; Signet Laboratories, Inc., MA, USA). Sections were microwave pretreated in citrate buffer (pH 6.0) for antigen retrieval. Endogenous peroxidase activity was blocked using 3% H_2O_2 in methanol. Sections were washed and blocked with goat serum for 10 min and incubated with the primary antibody for 1 h at room temperature. Immunohistochemical detection was performed using the labeled streptavidin biotin complex method (Histostain Plus Bulk Kit; Zymed Laboratories, Inc., San Francisco, CA). AEC (3-amino-9-ethylcarbazole) was used as a chromogen, and slides were counterstained with hematoxylin. Negative controls were comprised of supplementing the primary antibody with an isotype control. Blood vessel contours were highlighted by an intense reddish staining easily discernible from other background elements.

MVD. The MVD was computed using a computerized image analysis system composed of a trichip RGB video-camera (Sony, Japan) installed on a light microscope (Zeiss, Germany) and attached to an IBM-compatible personal computer (Pentium III, MMX, 450mhz, 125 MB RAM) equipped with a frame grabber. Histological images were captured, digitized, and displayed on a high-resolution color 17-inch monitor. The five most vascularized microscopic fields (“hot spots”) of the RCC tumors were selected for analysis using a medium-sized magnifying lens ($\times 100$) and loaded onto a 760×570 -pixels buffer with an area of 291.7 mm². The MVD parameter was measured using the Image Pro Plus 4 image analysis software (Media Cybernetics, Silver Spring, MD). MVD is presented as the mean percentage of the vessel area per microscopically computerized field.

Fractal Analysis of Microvessels. The box-counting method is widely used for calculating image fractal dimensions. This method allows for the determination of the fractal dimension of both scale-invariant and self-similar structures. To estimate the box-dimension, the Euclidean space containing the image is divided into a grid of boxes of size “s.” Then, the size, s, is changed to progressively smaller sizes, and the corresponding number of nonempty boxes are counted [N(s)]. The sequence of mesh sizes for grids is usually reduced by a factor of one-half from one grid to the next. The logarithm of N(s) versus the logarithm of 1/s gives a line whose gradient (slope) corresponds to the box dimension. Accordingly, a computer algorithm was programmed implementing the box-counting method (17) to compute the fractal dimensions of the microvessels visualized within the hot-spot microscopic fields.

The box-counting fractal dimension of each microscopic field is given by

$$D_b = \lim_{\epsilon \rightarrow 0} \frac{\log N(\epsilon)}{\log(1/\epsilon)}$$

where D_b is the box-counting fractal dimension of the vessel-containing field, ϵ is the side length of the box, and $N(\epsilon)$ is the smallest number of boxes of side-length ϵ required to completely cover the outlines of the vessels within the microscopic field. Because the limit 0 cannot be applied to natural objects or physical representations of mathematical fractal objects, the dimension was calculated by:

$D_b = d$, where d is the slope of the graph of $\log [N(\epsilon)]$ against $\log [1/\epsilon]$. As a measure of the goodness-of-fit of this relationship, the coefficient of determination (R^2) was computed in each case, presenting values of $R^2 > 0.95$.

The fractal dimension values range between 1 and 2. For classical geometric shapes such as a line, a square and a cube, the fractal dimension is identical to the classic (Euclidean) dimension, being 1 for the line, 2 for square, and 3 for a cube. However, a geometrical structure with a complex (tortuous) contour is best represented by the fractal dimension that is a rational number. The more branched and tortuous is the contour of the blood vessels in RCC, the larger is the fractal dimension. The higher the vessel complexity (displaying branching and tortuous vessels), the closer to 2 is the fractal dimension value. The mean values of the fractal dimensions (MFDs) of all of the fields analyzed per case were used for statistical evaluation.

The box-counting method for computing the MFD was applied to the same hot-spot microscopic fields used for the MVD determination.

The MFD was computed in the RCC tumors as well as in the vascular network surrounding the proximal tubules of non-tumorous kidney away from the primary tumor mass.

Statistical Analysis. Univariate comparisons between continuous parametric groups were performed using the paired or unpaired t test, as appropriate. The equality of variances was tested using the Levene’s test. Multiple parametric groups were compared using ANOVA and then the Bonferroni post hoc test. The multivariate logistic regression model was used to examine the relationship between vascular parameters, grade, and the presence of tumor necrosis. Kaplan-Meier curves were constructed, and the log-rank test was used for univariate survival analysis of the vascular parameters. Multivariate survival analysis of vascular and other parameters (*e.g.*, age, gender, and grade) was performed using Cox’s proportional hazard regression model, operating in a forward stepwise mode. Two-tailed P s of ≤ 0.05 were considered to be statistically significant.

RESULTS

Clinicopathological Parameters. Tumors from 17 females and 32 males with low-stage RCC (2 with stage T1 and 47 with stage T2) with mean age of 65 ± 9.0 years were studied. Patient follow-up for 5 years or more was available. Tumor size ranged from 2.5 to 15 cm, with a mean size of 6.7 ± 3.5 cm. Twenty-one tumors (43%) displayed low Fuhrman nuclear grade, whereas 28 tumors (57%) displayed high nuclear grade (23 grade-III tumors and 4 grade-IV tumors).

A significant correlation was found between tumor grade and poor prognosis ($P = 0.04$; log-rank test). Thus, by the end of the follow-up period, lower survival rates were seen in high-grade (74%) than in low-grade tumors (96%). A significant correlation was found between the extent of tumor necrosis and patient prognosis. Patients with tumors exhibiting no or <25%




Fig. 1 Representative sections of RCC immunohistochemically stained for CD34. A, tumor with a high MVD ($\times 100$). B, tumor with a low MVD ($\times 100$).

macroscopic necrosis showed higher survival rates (97%) than patients with tumors with $>25\%$ necrosis (31%; $P = 0.0001$).

Tumor Microvascular Density. Representative CD34-stained sections of RCCs with low and high MVD values are seen in Fig. 1. Although MVD was higher in low-grade as opposed to high-grade tumors (MVD = $11.5 \pm 3.5\%$ versus $9.4 \pm 5.2\%$), the difference was not statistically significant ($P = 0.12$; Table 1). Non-necrotic tumors were more vascularized (MVD = $10.9 \pm 4.4\%$) as compared with necrotic tumors (MVD = $7.15 \pm 4.6\%$; $P = 0.03$; Table 1). Survival analysis revealed that MVD was higher in patients who survived longer than 5 years (MVD = $10.8 \pm 4.7\%$) as compared with those who died before the end of the 5-year follow-up period (MVD = $6.4 \pm 3.7\%$; $P = 0.03$; Table 1). As seen in Fig. 2, a best-cutoff point of MVD = 10% was detected according to which patients with tumors exhibiting a MVD of $>10\%$ had better survival rates (96%), as compared with tumors with MVD $\leq 10\%$ who present lower survival rates (72%; $P = 0.02$; log-rank test).

Table 1 Relationship between tumor grade, necrosis, patient survival, and vascular parameters

	MVD ^a (mean \pm SD)	<i>P</i>	MFD ^b (mean \pm SD)	<i>P</i>
Tumor grade ^c				
Low	$11.5 \pm 3.5\%$	0.12	1.55 ± 0.11	0.03
High	$9.4 \pm 5.2\%$		1.45 ± 0.15	
Tumor necrosis ^d				
No	$10.9 \pm 4.4\%$	0.03	1.52 ± 0.12	0.01
Yes	$7.1 \pm 4.6\%$		1.38 ± 0.17	
Survival				
≥ 5 yrs	$10.8 \pm 4.7\%$	0.03	1.56 ± 0.11	0.02
< 5 yrs	$6.4 \pm 3.7\%$		1.46 ± 0.15	

^a Expressed as the mean percentage of the vessel area per microscopically computerized field.

^b Expressed in absolute units.

^c Low grade tumors, Fuhrman grade I and II; high grade tumors, Fuhrman grade III and IV.

^d Tumors were considered necrotic if they exhibited $>25\%$ macroscopic necroses.

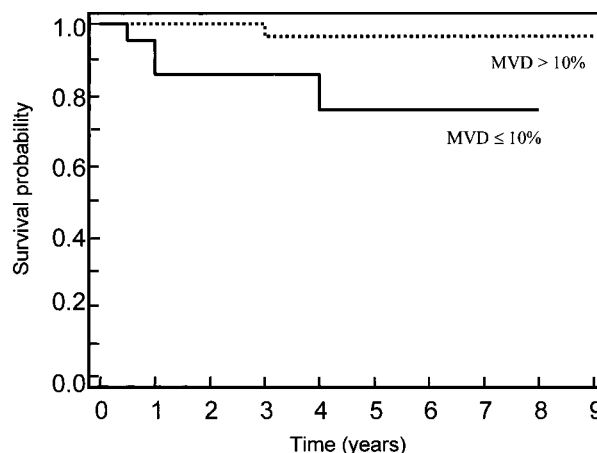


Fig. 2 Kaplan-Meier survival curve for RCC patients using a MVD of 10% as a cutoff point ($P = 0.02$).

Tumor MFD. Fig. 3 shows two representative CD34-stained microscopic fields of RCCs with low and high MFD values. A significantly higher vascular complexity was noted in low-grade tumors, MFD = 1.55 ± 0.11 , in comparison with high-grade tumors, MFD = 1.45 ± 0.15 ($P = 0.03$; Table 1). Non-necrotic tumors exhibited a more complex vascular architecture (MFD = 1.52 ± 0.12) as compared with necrotic tumors (MFD = 1.38 ± 0.17 ; $P = 0.01$; Table 1). The MFD was significantly higher in patients who survived longer than 5 years (MFD = 1.56 ± 0.11) as compared with those who did not (MFD = 1.46 ± 0.15 ; $P = 0.02$; Table 1). As seen in Fig. 4 a best-cutoff point of MFD = 1.55% was detected, according to which all patients with tumors having MFD $>1.55\%$ had survived by the end of the study period, as opposed to 78% of the patients with tumors having an MFD $\leq 1.55\%$ ($P = 0.03$; log-rank test).

The MFD was also measured in 10 sections of normal kidney, in the cortical region of the proximal tubules, away from the primary tumor. The MFD of the normal renal microvasculature was lower than in the adjacent tumors (MFD = 1.38 ± 0.06 versus 1.53 ± 0.06 ; $P = 0.0002$; paired Student *t* test).

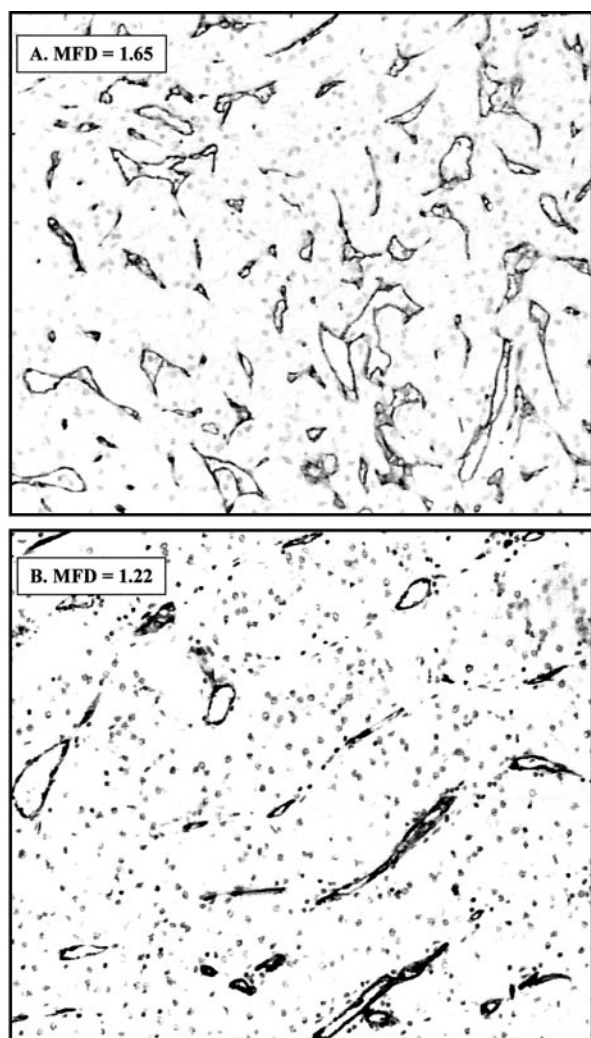


Fig. 3 Representative sections of RCC immunohistochemically stained for CD34. A, tumor with a high MFD ($\times 100$). B, tumor with a low MFD ($\times 100$).

Multivariate logistic regression analysis revealed that the MFD was the only significant independent factor associated with the extent of tumor necrosis. The Cox proportional hazard model was applied to all of the variables included in the study. The extent of tumor necrosis was the only independent significant predictor of patient survival ($P = 0.002$; $\beta = 0.88$; relative risk = 2.42).

DISCUSSION

This study is an attempt to elucidate further the clinical utility of tumor MVD as a prognostic factor in RCC patients. We also felt that the analysis of the architectural complexity of the vascular network would lead to a more complete understanding of the role of MVD in RCC pathology. This is the first report to reveal that measurement of tumor microvascular complexity has prognostic utility in any tumor. For this purpose, the mean value of the tumor MFD was computed. The fractal dimension is a geometric description of an image. It has an integer value for topological sets and a non-integer value for fractal sets (18). Different methods

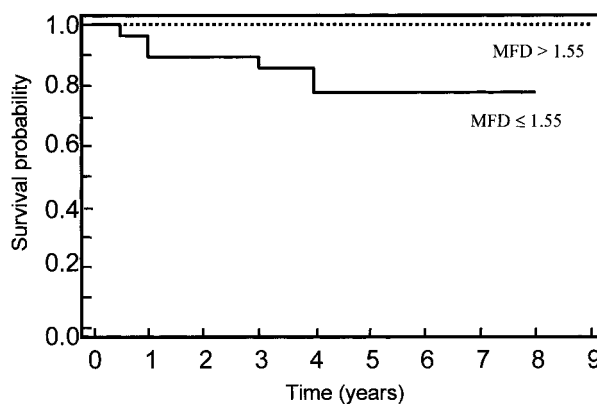


Fig. 4 Kaplan-Meier survival curve for RCC patients using a MFD of 1.55 as a cutoff point ($P = 0.03$).

for computing the fractal dimension of a structure exist; each define several variants of the fractal dimension concept. Examples include the Hausdorff dimension (18, 19), correlation dimension (19), the information dimension (19) and the box dimension (19). We used the latter to compute the MFD in RCCs because this method has the most applications in science (19).

Tumor angiogenesis is a dynamic process mediated by vascular growth factors and their receptors (20, 21). Complex modulating interactions between tumor cells, endothelial cells, and matrix metalloproteinases establish the final density and complexity of the tumor microvasculature (20). Quantitation of the MVD in various solid malignant tumors provides an indication for the risk of developing metastases (22) as well as for patient survival (1). In numerous malignant tumors, it has been demonstrated that abundant tumor vascularity is associated with greater risk of tumor progression (23). It is generally accepted that tumors which lack the ability to induce adequate neovascularization are associated with limited growth and invasive potential. The prognostic significance of tumor MVD in RCC patients is controversial. In contrast to other neoplasms, certain studies describe an inverse correlation between MVD and the histological grade (7) and a positive correlation with patient survival (2, 3). Others (4, 5) reported a negative correlation between MVD and survival, and one study did not find any statistical correlation between MVD and prognosis (6).

Our findings that increased tumor MVD is associated with lower tumor grade and improved patient survival support the findings of Delahunt *et al.* (2), and Herbst *et al.* (3) and are somewhat paradoxical. It is not clear why poorly vascularized RCC tumors exhibit a worse prognosis. In this respect, RCC differs from other solid malignancies. Certain hypotheses addressing this paradox have been attempted. Kohler *et al.* (7) suggested that the decreased MVD in high-grade RCCs reflects the inability of tumor neovascularization to keep pace with the proliferation of the high-grade tumor cells, and increased tumoral vessel permeability may compensate for their reduced amount. An additional mechanism explaining this paradox may be related to architectural remodeling of the tumor vascularity influenced by tumor progression (2). Thus, in high grade tumors, the development of large vascular channels within a tumor would have the effect of decreasing the measured MVD values without necessarily altering the total vascular area and blood

supply of these tumors (2). Herbst *et al.* (3) considered the RCC microvasculature as a potential parameter of tumor differentiation. The renal tubular system is closely associated with a highly vascularized stroma, and inasmuch as RCC originates from the renal proximal tubular system, it is not surprising that a well-differentiated, low-grade RCC has an abundant vascular stroma (3). Finally, this paradox may be related to the architectural pattern of the tumor growth characteristics of RCC, which is in contrast with the growth patterns of other tumors where MVD is strongly associated with aggressive behavior such as carcinoma of the breast. Breast carcinomas have an infiltrative pattern of growth, whereby tumor epithelial/host stromal interactions play a key role in tumor progression. In these tumors, increased stromal angiogenesis will lead to a more rapidly infiltrating tumor. RCC typically grows as a well-demarcated bulging mass with a delicate vascular stroma. A well-vascularized RCC will continue to enlarge slowly as a mass lesion. A high-grade solid RCC enlarges more rapidly, overcoming its vascular network and decreasing its architectural complexity. A poorly vascularized tumor will become hypoxic and necrotic. As the tumor becomes necrotic, viable tumor cells may gain access to the vascular system, leading to tumor dissemination. Our observation that, subsequent to multivariate analysis, macroscopic tumor necrosis was the only independent, poor prognostic factor supports this hypothesis further.

An additional characteristic of tumor angiogenesis to be considered is the degree of vascular complexity. A recent review of tumor angiogenesis emphasized the importance of vascular architectural complexity in cancer biology (11). Heymans *et al.* (14) recently reported that malignant melanomas have distinct patterns of vessel complexity as measured by fractal analysis. In experimental tumor models, Baish and Jain (13) showed that malignant tumors have a much higher vascular complexity as compared with normal vasculature. Our findings that the MFD was always higher in RCC than in the adjacent normal kidney supports these observations. Fractal analysis of the architectural vascular network in RCC showed that a complex RCC vasculature correlates with lower grade and better prognosis. How can we elucidate our observation that tumors with increased MFD, *i.e.*, more chaotic or random vessel branching, behave better than those with lower MFD? The more complex vascular pattern defined by increased MFD may reflect a more complete vascularization of the tumor, albeit a disordered vasculature. This explanation is also consistent with our findings that increased MVD correlates with improved patient survival, as described earlier. The fact that the only independent parameter to significantly correlate with the extent of tumor necrosis was the degree of RCC vascular complexity provides additional support of this theory.

In summary the analysis of tumor microvascular complexity may provide additional prognostic information as well as shed light on the complex interactions between tumor angiogenesis and growth.

ACKNOWLEDGMENTS

We thank Laura Frajewicki for the laboratory technical assistance.

REFERENCES

- Weidner, N. Tumoral vascularity as a prognostic factor in cancer patients: the evidence continues to grow. *J. Pathol.*, *184*: 119–122, 1998.
- Delahunt, B., Bethwaite, P. B., and Thornton, A. Prognostic significance of microscopic vascularity for clear cell renal cell carcinoma. *Br. J. Urol.*, *80*: 401–404, 1997.
- Herbst, C., Kosmehl, H., Stiller, K. J., Berndt, A., Eiselt, M., and Schubert, J. Evaluation of microvessel density by computerized image analysis in human renal cell carcinoma. Correlation to pT category, nuclear grade, proliferative activity and occurrence of metastasis. *J. Cancer Res. Clin. Oncol.*, *124*: 141–147, 1998.
- Yoshino, S., Kato, M., and Okada, K. Prognostic significance of microvessel count in low stage renal cell carcinoma. *Int. J. Urol.*, *2*: 156–160, 1995.
- Nativ, O., Sabo, E., Reiss, A., Wald, M., Madjar, S., and Moskovitz, B. Clinical significance of tumor angiogenesis in patients with localized renal cell carcinoma. *Urology*, *51*: 693–696, 1998.
- MacLennan, G. T., and Bostwick, D. G. Microvessel density in renal cell carcinoma: lack of prognostic significance. *Urology*, *46*: 27–30, 1995.
- Kohler, H. H., Barth, P. J., Siebel, A., Gerharz, E. W., and Bittinger, A. Quantitative assessment of vascular surface density in renal cell carcinomas. *Br. J. Urol.*, *77*: 650–654, 1996.
- Cross, S. S. Fractals in pathology. *J. Pathol.*, *182*: 1–8, 1997.
- Sevidy, R., Windischberger, C. H., Svozil, K., Mosner, E., and Breitenacker, G. Fractal analysis: an objective method for identifying atypical nuclei in dysplastic lesions of the cervix uteri. *Gynecol. Oncol.*, *75*: 78–83, 1999.
- Luzi, P., Bianciardi, G., Miracco, C., Desanti, M. M., Del Vecchio, M. T., Alia, L., and Tosi, P. Fractal analysis in human pathology. *Ann. NY Acad. Sci.*, *879*: 255–257, 1999.
- Baish, J. W., and Jain, R. K. Fractals and cancer. *Cancer Res.*, *60*: 3683–3688, 2000.
- Gazit, Y., Berk, D. A., Leunig, M., Baxter, L. T., and Jain, R. K. Scale-invariant behavior and vascular network formation in normal and tumor tissue. *Phys. Rev. Lett.*, *75*: 2428–2431, 1995.
- Gazit, Y., Baish, J. W., Safabakhsh, N., Leung, M., Baxter, L. T., and Jain, R. K. Fractal characteristics of tumor vascular architecture during growth and regression. *Microcirculation*, *4*: 395–402, 1997.
- Heymans, O., Blacher, S., Brouers, F., and Pierard, G. E. Fractal quantification of the microvasculature heterogeneity in cutaneous melanoma. *Dermatology*, *198*: 212–217, 1999.
- Beahrs, O. H., Henson, D. E., Hutter, R. V. P., Meyers, M. H. (eds.). American Joint Committee on Cancer: Manual for Staging of Cancer, Ed. 4, pp. 201–202. Philadelphia: J. B. Lippincott Co., 1992.
- Fuhrman, S. A., Lasky, L. C., and Limas, C. Prognostic significance of morphologic parameters in renal cell carcinoma. *Am. J. Surg. Pathol.*, *6*: 655–663, 1992.
- Cross, S. S., Cotton, D. W. K., and Underwood, J. C. E. Measuring fractal dimensions: sensitivity to edge-processing functions. *Anal. Quant. Cytol. Histol.*, *16*: 375–378, 1994.
- Mandelbrot, B. B. *The Fractal Geometry of Nature*, pp. 14–19. New York: W. H. Freeman and Company, 1982.
- Peitgen, H. O., Jurgens, H., and Saupe, D. *Chaos and fractals*. New Frontiers of Science, Chapters 4 and 12, pp. 202–219, 735, 738. New York: Springer-Verlag New York, Inc., 1992.
- Yancopoulos, G. D., Davis, S., Gale, N. W., R, J. S., Wiegand, S. J., and Holash, J. Vascular-specific growth factors and blood vessel formation. *Nature (Lond.)*, *407*: 242–248, 2000.
- Carmeliet, P., and Jain, R. K. Angiogenesis in cancer and other diseases. *Nature (Lond.)*, *407*: 249–257, 2000.
- Vermeulen, P. B., Gasparini, G., Fox, S. B., Toi, M., Martin, K., McCulloch, P., Pezzella, F., Viale, G., Weidner, N., Harris, A. L., and Dirix, L. Y. Quantification of angiogenesis in solid human tumors. An international consensus on the methodology and criteria of evaluation. *Eur. J. Cancer*, *32*: 2474–2484, 1996.
- Weidner, N. Angiogenesis as a predictor of clinical outcome in cancer patients. *Hum. Pathol.*, *31*: 403–404, 2000.